



Femme de 76 ans,

Cl: néo du rectum + Loc. II Foie + Poumon

Pas de symptomatologie pulmonaire

Pas de Signe infectieux net

Traitement : Eloxatine- Avastin puis Xeloda



LESION PARACOSTALE

Neurologie Clinique de l'Enfant

ID : 201222

20/05/2010

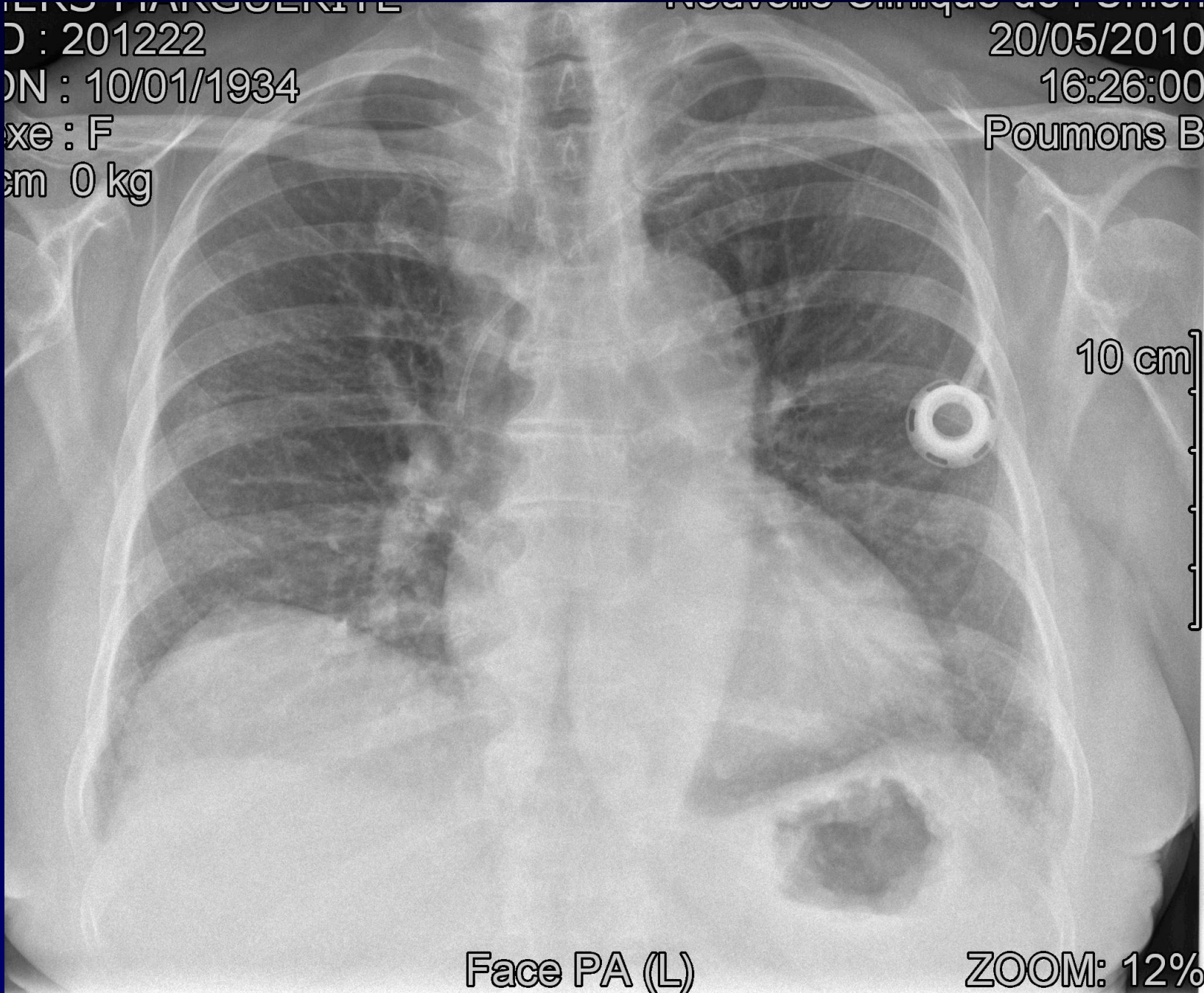
DATE : 10/01/1934

16:26:00

Sexe : F

Poumons B

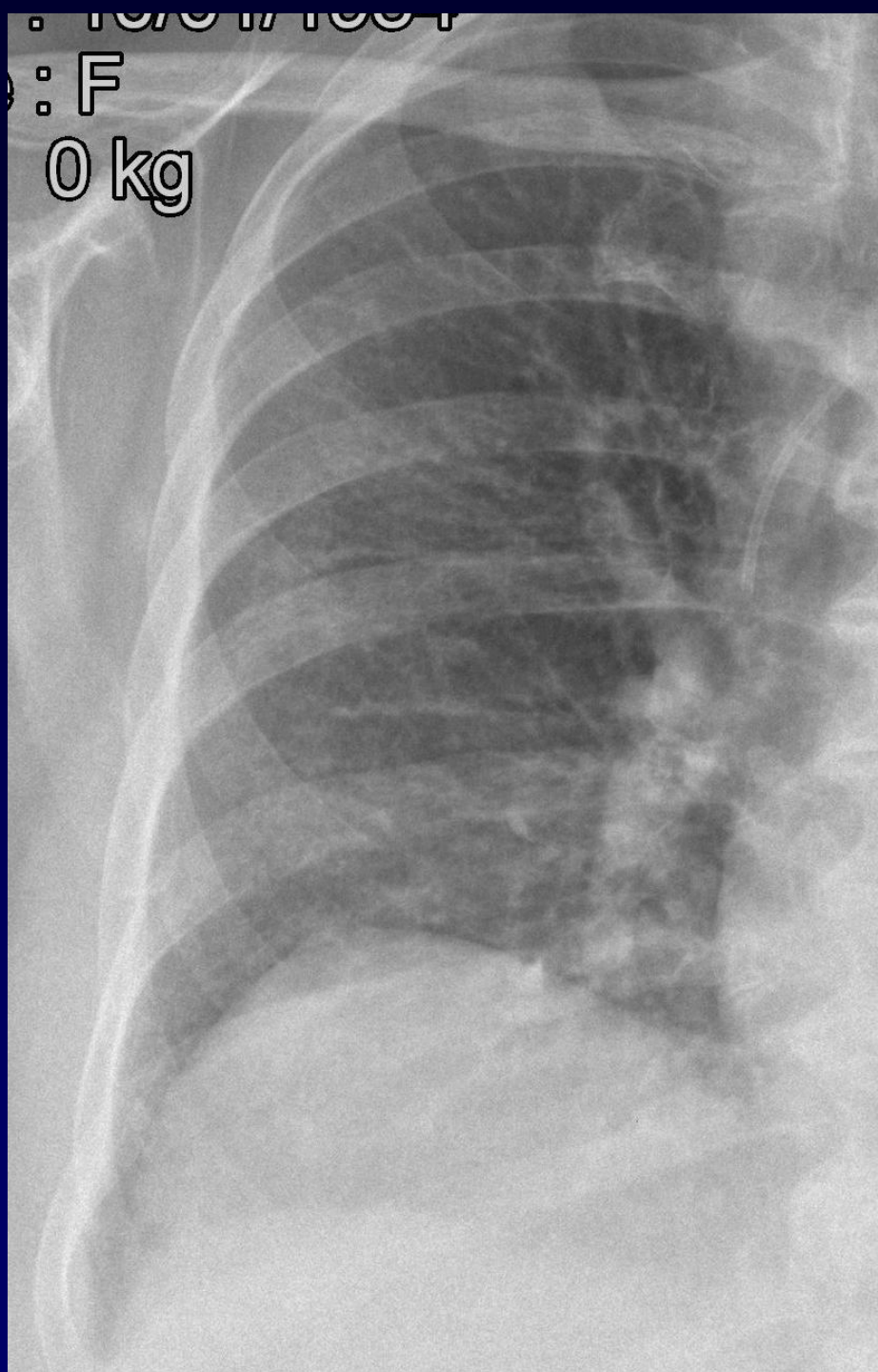
Poids : 0 kg



10 cm

Face PA (L)

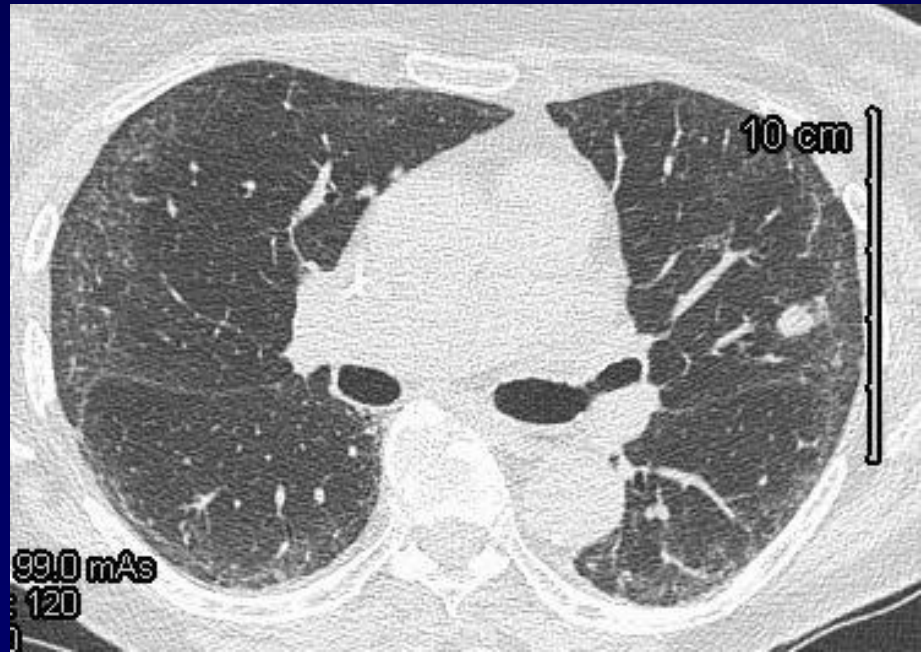
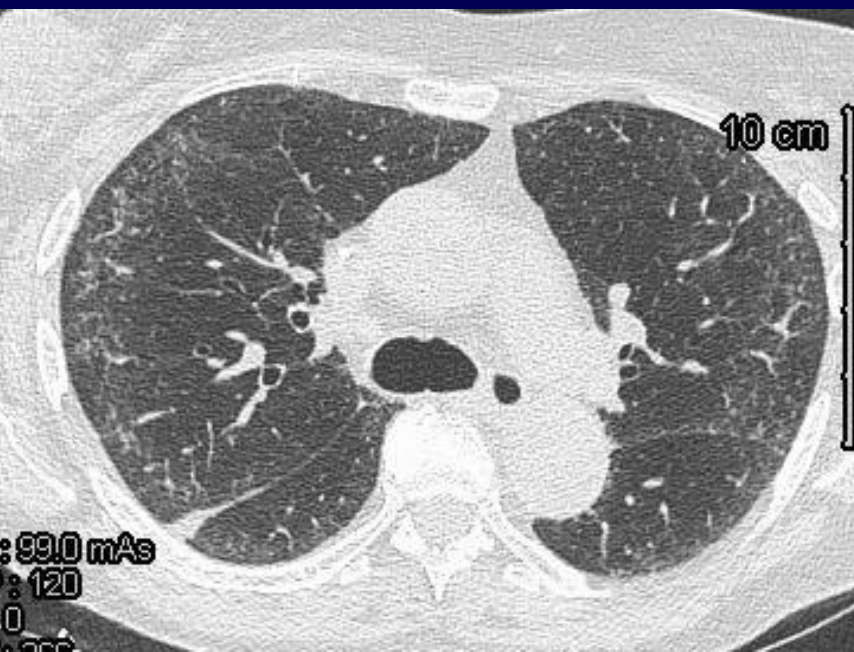
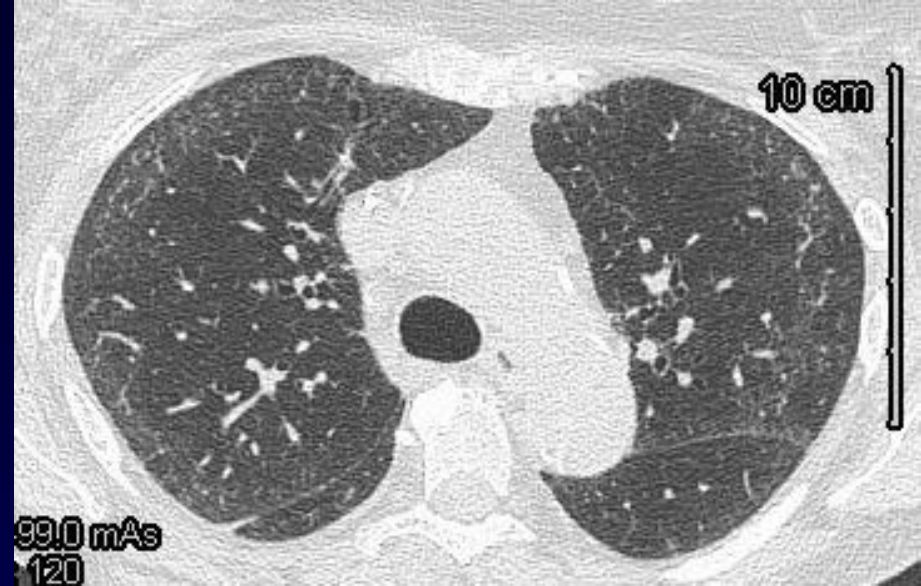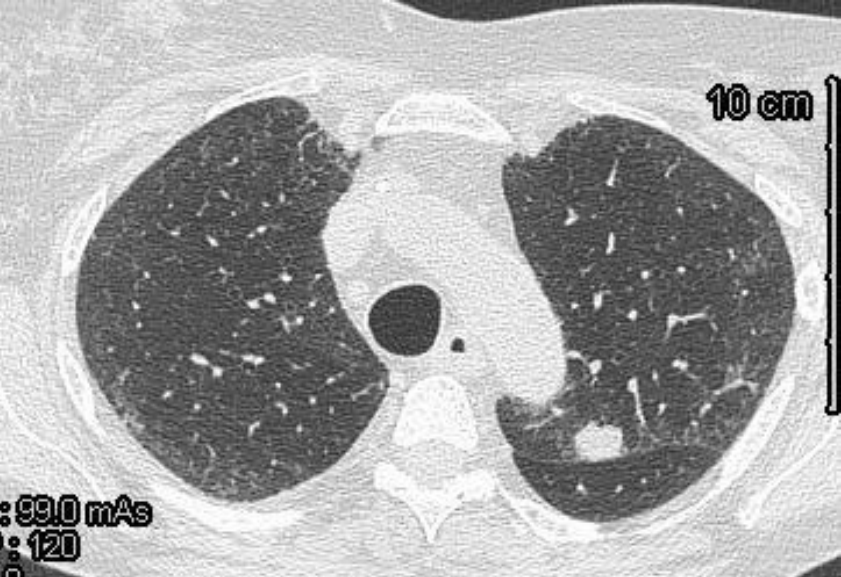
ZOOM: 12%

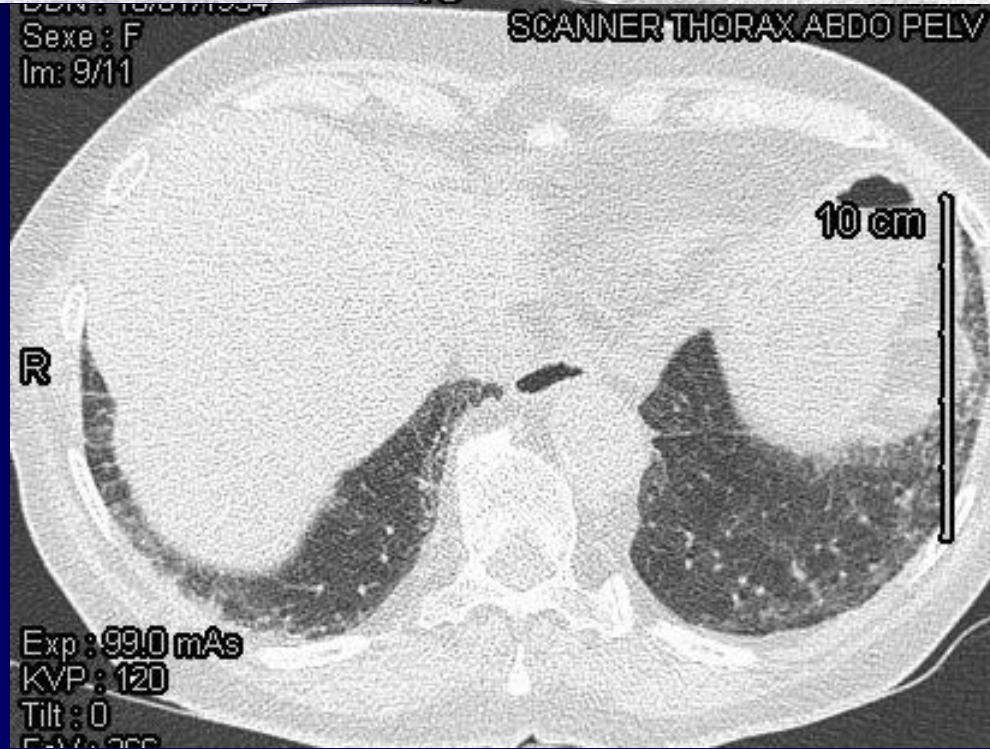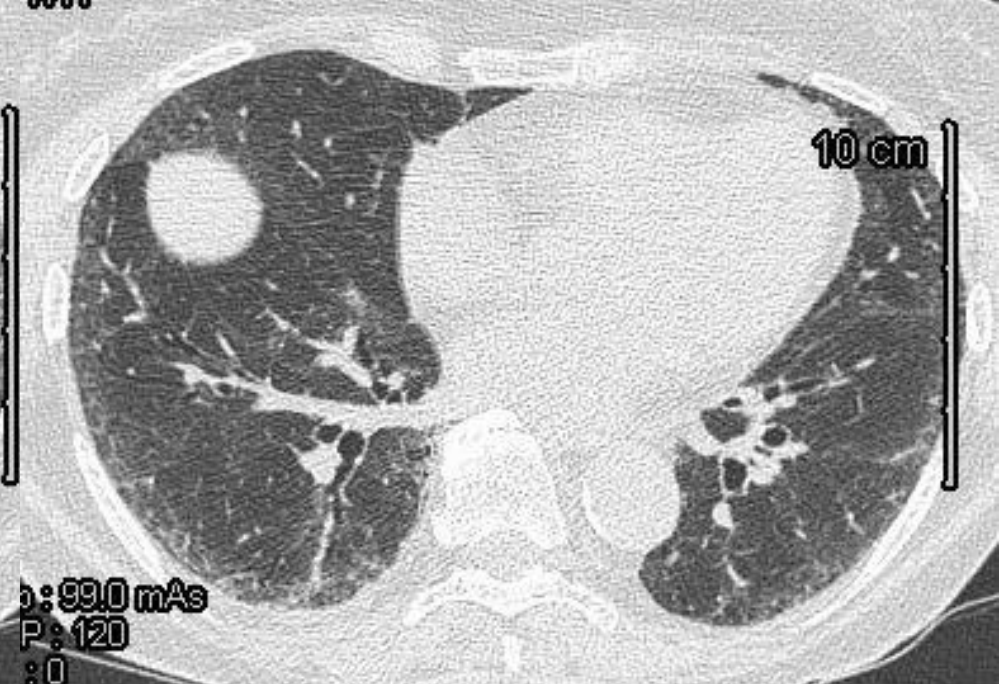
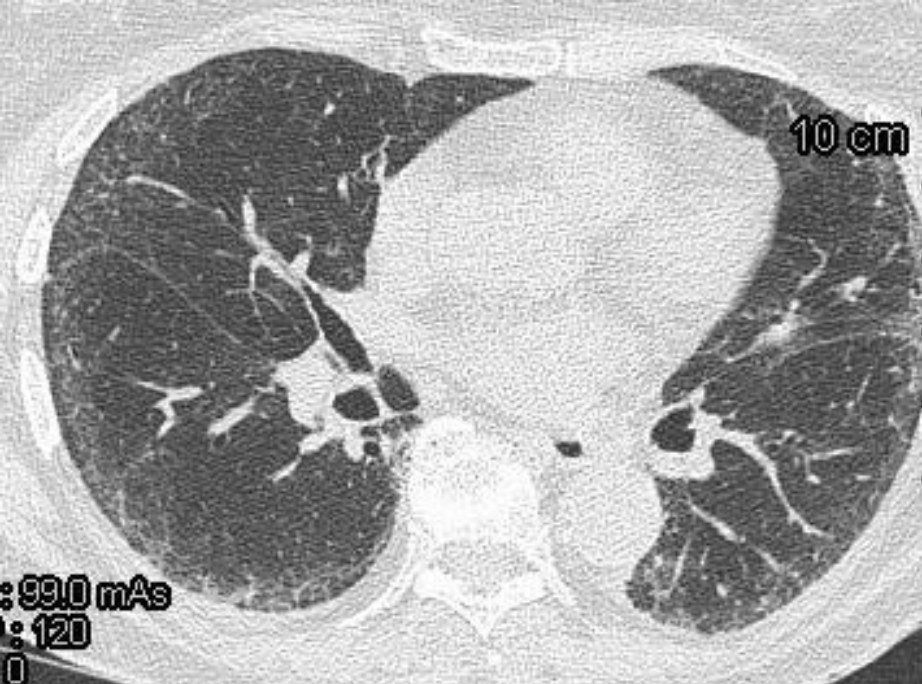


• 10/0/100/1

: F

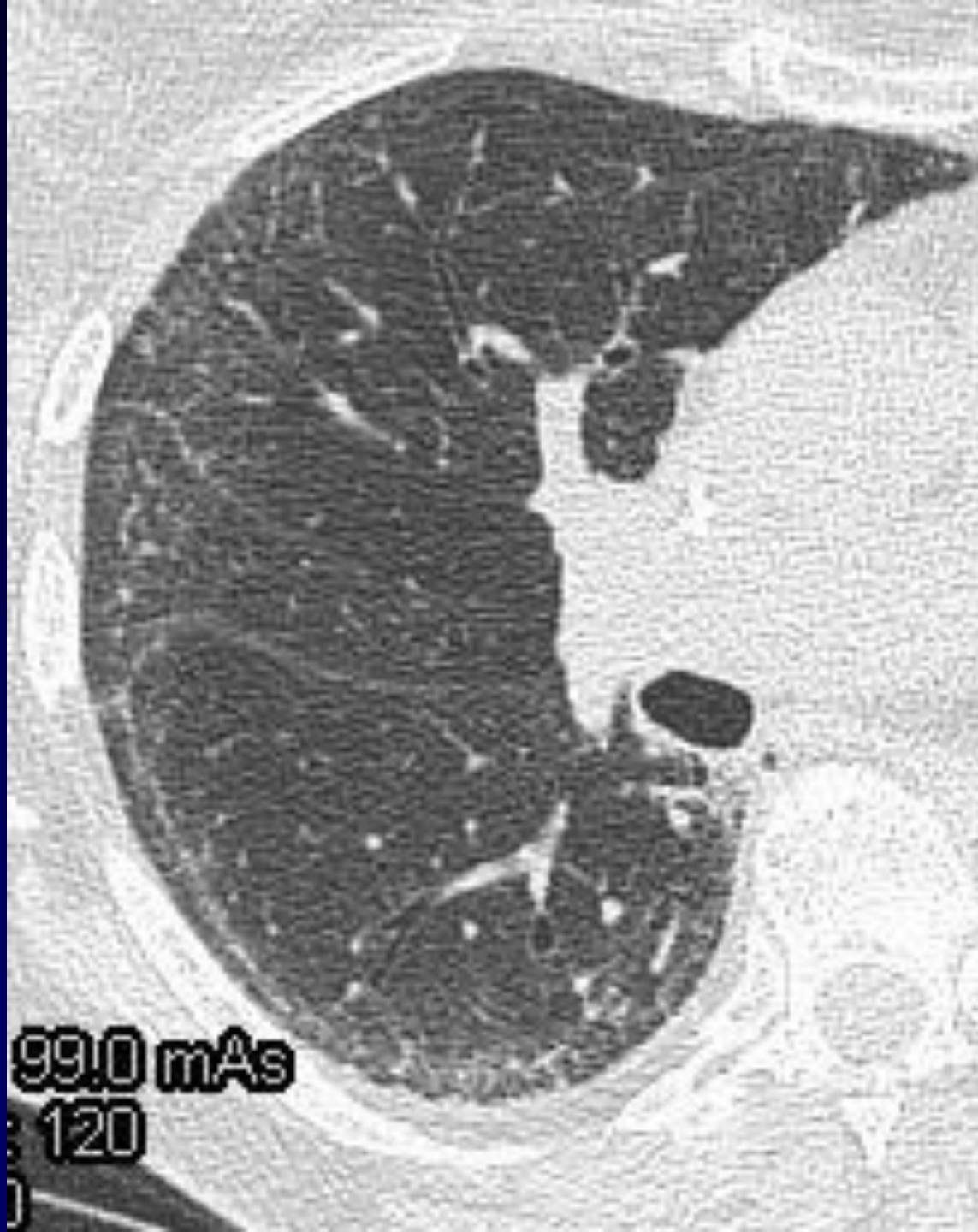0 kg



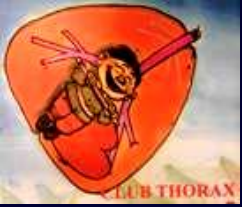



**Diagnostic ?**



99.0 mAs  
120



# Diagnostic

NSIP ?

**Oxaliplatine ou 5 FU**

Jeanfaivre T, Saint-André J P, Lainé P, Tuchais E. Fibrose pulmonaire aiguë au décours d'un traitement par fluorouracile et cisplatine. *Therapie* 1995; 50: 167-169

Yagüe XH, Soy E, Merino BQ, Puig J, Fabregat MB, Colomer R. Interstitial pneumonitis after oxaliplatin treatment in colorectal cancer. *Clin Transl Oncol*. 2005 Dec;7(11):515-7



# Bibliographie

Jeanfaivre T, Saint-André J P, Lainé P, Tuchais E. Fibrose pulmonaire aiguë au décours d'un traitement par fluorouracile et cisplatine. *Thérapie* 1995; 50: 167-169

Yagüe XH, Soy E, Merino BQ, Puig J, Fabregat MB, Colomer R. Interstitial pneumonitis after oxaliplatin treatment in colorectal cancer. *Clin Transl Oncol.* 2005 Dec;7(11):515-7